

CASE REPORT

Hepatocellular adenomas associated with anabolic androgenic steroid abuse in bodybuilders: a report of two cases and a review of the literature

L Socas, M Zumbado, O Pérez-Luzardo, A Ramos, C Pérez, J R Hernández, L D Boada

Br J Sports Med 2005;**39**:e27 (<http://www.bjsportmed.com/cgi/content/full/39/5/e27>). doi: 10.1136/bjsm.2004.013599

Anabolic androgenic steroids (AAS) are used illicitly at high doses by bodybuilders. The misuse of these drugs is associated with serious adverse effects to the liver, including cellular adenomas and adenocarcinomas. We report two very different cases of adult male bodybuilders who developed hepatocellular adenomas following AAS abuse. The first patient was asymptomatic but had two large liver lesions which were detected by ultrasound studies after routine medical examination. The second patient was admitted to our hospital with acute renal failure and ultrasound (US) studies showed mild hepatomegaly with several very close hyperecogenic nodules in liver, concordant with adenomas at first diagnosis. In both cases the patients have evolved favourably and the tumours have shown a tendency to regress after the withdrawal of AAS. The cases presented here are rare but may well be suggestive of the natural course of AAS induced hepatocellular adenomas. In conclusion, sportsmen taking AAS should be considered as a group at risk of developing hepatic sex hormone related tumours. Consequently, they should be carefully and periodically monitored with US studies. In any case, despite the size of the tumours detected in these two cases, the possibility of spontaneous tumour regression must also be taken in account.

A growing number of reports of anabolic androgenic steroid (AAS) misuse in Western Europe and the USA by non-competitive athletes, especially bodybuilders, has emerged, especially since the beginning of the 1990s.¹ In fact, a wide range of anabolic steroids are being self administered.¹⁻² AAS are used at high doses by bodybuilders to achieve a rapid increase in muscle mass. Although the use of anabolic steroids is associated with a number of side effects,³ the prevalence of toxic effects following AAS administration is difficult to ascertain because of under-reporting. Nevertheless, it is becoming increasingly clear that the abuse of AAS is associated with serious adverse effects affecting the liver and the cardiovascular, central nervous, musculoskeletal, endocrine, and reproductive systems. Several liver disorders have been reported to be associated with AAS consumption, namely cholestasis, peliosis hepatis, and liver tumours.¹⁻³ Although most of these tumours are benign, early detection is important in order to avoid the associated risks of life threatening haemorrhages and malignant degeneration.⁴ These hepatic alterations are caused almost exclusively by 17 α -alkylated AAS.¹⁻³

CASE REPORT 1

In this first study we report a 35 year old male bodybuilder who has been taking AAS at high doses over the last 15 years.

During this period a number of AAS were self administered in cycles of 8 weeks with a suspension period of 2 weeks between cycles. The following AAS were the most frequently consumed by the patient: (a) oral: stanozolol and oxymetholone; and (b) parenteral: nandrolone decanoate, testosterone enanthate, and methenolone enanthate.

The doses and the frequency of self administration were, approximately, 400 mg daily for oral AAS and 600 mg twice or three times a week for parenteral AAS, varying in each cycle.

The patient was completely asymptomatic, with no signs of jaundice, when he was included in an experimental follow up examination programme for bodybuilders. In general terms, there was no relevant previous history. Neither daily intake of ethanol or smoking were reported. In the clinical examination performed shortly after admission to the program, our patient showed severe hepatomegaly. Laboratory evaluation revealed slight damage of liver function (ALT: 75 IU/l; AST: 53 IU/l; alkaline phosphatase: 403 IU/l; GGT: 60 IU/l; total bilirubin: 1.6 mg/ml; direct bilirubin: 0.42 mg/dl) and muscular damage (CPK: 298 IU/l). Coagulation tests were entirely normal, as were serum levels of alfa-fetoprotein (AFP). Hepatitis virus markers, including hepatitis B and C, were negative. Serum levels of sex hypophyseal hormones (FSH and LH) were evaluated but were not detectable.

Abdominal ultrasound (US) showed two large hyperecogenic lesions in the liver, one in the left lobe (6 cm in size) and another in the right (12 cm in size). The largest lesion showed a heterogeneous pattern, thus indicating the existence of haemorrhage areas in the tumour. In colour power Doppler ultrasonography blood flow signals could only be detected at the peripheral areas of both tumours. These results are concordant with adenomas at first diagnosis (fig 1).

Cytology was performed by fine needle puncture-aspiration (FPA) of the nodules. The cytological samples did not reveal any malignancy. Subsequently, the patient was subjected to magnetic resonance imaging (MRI). The MRI study confirmed the diagnosis of liver cell adenomas (fig 2A and B). T1 weighted MRI showed a heterogeneous signal in both tumours, although this heterogeneity was more intense in the lesion of the right lobe. In T2 weighted MRI, the lesions showed an intense mixed pattern, more pronounced in the largest tumour, thus indicating the presence of necrotic and/or haemorrhagic areas in the lesion. The absence of any other risk factor and the previous history of AAS consumption at high doses allowed us to establish the aetiology of the liver tumours: hepatic adenomas secondary to AAS abuse. Given

Abbreviations: AAS, anabolic androgenic steroids; AFP, alfa-fetoprotein; FPA, fine needle puncture-aspiration; HA, hepatic adenomas; HCC, hepatocellular carcinomas; MRI, magnetic resonance imaging; US, ultrasound

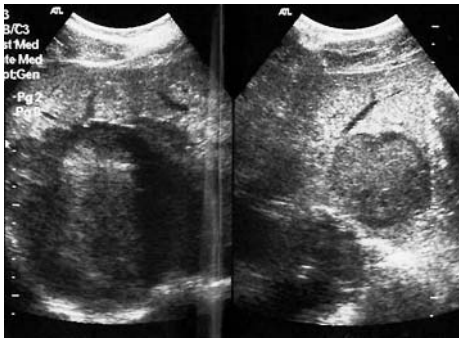


Figure 1 Abdominal ultrasound showing large hyperechoic lesions in the liver of the first patient.

the considerable size of the lesions, it was not possible to establish any therapeutic guidelines, with the exception of absolute prohibition on self administering AAS and the inclusion of this patient in a liver transplantation program. The patient has been followed biannually by means of US and analytical studies.

The patient was subjected to clinical, radiological, and analytical tests 1 year after diagnosis. Biochemical values showed a persistent slight alteration in liver function. AFP serum levels stayed normal, while US studies demonstrated that the lesions had remained unaltered and of the same size as the year before the persistent slight alteration. To confirm the absence of any malignancy, a biopsy under ecographic control was performed. The histological findings showed neither portal tract in the tumour nor capsule formation around it. The nuclei of the tumour cells showed mild atypia and a low degree of anisonucleosis. These histopathological results confirmed again that the lesions were non-malignant tumours.

At present, 4 years after the diagnosis and subsequent to further ecographic examinations, to our surprise, there has been a slight decrease in the size of the tumours (of about 1–2 cm in the tumour in the left lobe and 3–4 cm in the tumour in the right lobe) (not shown). Liver function has also clearly improved. Serum levels of transaminases have returned to normal, as have the other serum markers of liver function. As in previous examinations, coagulation tests and serum levels of AFP were absolutely normal. On the other hand, the serum levels of sex hypophyseal hormones (FSH and LH) were evaluated and found to be normal, thus suggesting that the withdrawal of AAS may have induced the total recovery of the hypothalamic-hypophyseal axis. However, the patient continues in the above mentioned liver transplantation program and undergoes periodic examination because of

the enormous size and the potential malignant transformation of the liver lesions.

CASE REPORT 2

We report another patient, a 23 year old male bodybuilder, with diverse severe symptoms and signs affecting different organs and systems due to misuse of various AAS at high doses. The patient had commenced treatment with AAS (and diuretics) 6 months before the appearance of the symptoms and had undertaken stringent diets for increasing muscle mass prior to competition. AAS were administered in cycles of 8 weeks, twice or three times a week, varying in each cycle, with a suspension period of 2 weeks between cycles. Each week the bodybuilder self administered the following AAS: (a) oral: stanozolol and oxymetholone; and (b) parenteral: nandrolone decanoate, testosterone phenylpropionate, and boldenone.

His nutrition also went through cycles. During the first 3 months he followed a hypercaloric and hyperproteinic diet to build up muscle mass. There then followed a phase of reduced caloric intake to lessen subcutaneous fat. He also severely restricted Na^+ and water intake and self administered a diuretic, torasemide, to attain better muscle contour definition by reducing extracellular and subcutaneous tissue volume.

The patient began to show symptoms after 6 months of treatment with AAS and 1 month of treatment with diuretics and a restrictive diet. He then stopped training and drug self administration and was admitted to the emergency service of our hospital in a confused state. The patient displayed asthenia and anorexia of 1 month duration. Analytical data reflected acute renal failure (urea: 304 mg/100 ml; creatinin: 10.2 mg/100 ml), muscular damage (myoglobinuria; CPK: 5499 IU/l; ALT: 178 IU/l; AST: 130 IU/l; LDH: 716 IU/l), metabolic alkalosis (pH: 7.62; Pco_2 : 66.1 mm Hg; Po_2 : 80.6 mm Hg; HCO_3^- : 77.8 mmol/l), hypokalaemia (K^+ : 2.12 mEq/l), and hypernatraemia (Na^+ : 147 mEq/l). Neither a daily ethanol intake or smoking were reported. It is well established that AAS induce fluid retention with hypernatraemia. Excess Na^+ in the blood produces an increasing rate of K^+ and H^+ excretion, inducing metabolic alkalosis and hypokalaemia and, consistently, a decrease in the respiratory frequency with compensatory respiratory acidosis. The marked hypokalaemia suffered by the patient could be explained by the fact that this bodybuilder did not maintain an adequate Na^+ , K^+ and water intake over the training periods, and, furthermore, self administered a loop diuretic. This marked hypokalaemia favoured muscle damage and rhabdomyolysis. Furthermore, the high doses of self administered AAS presumably promoted aggression and other changes in attitude that could explain the excess training

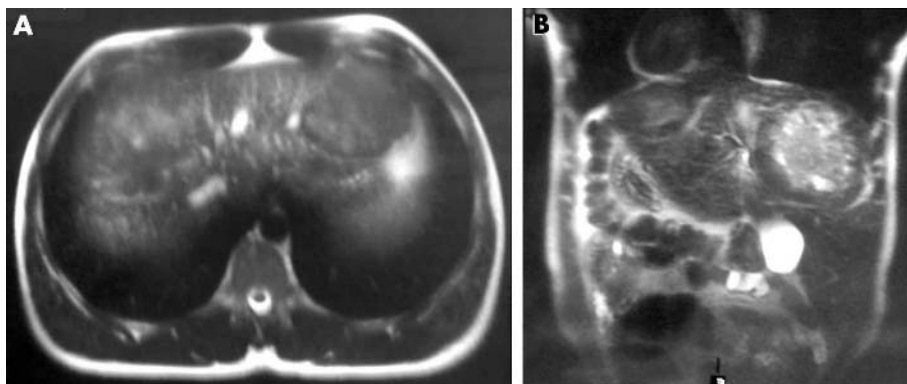


Figure 2 Magnetic resonance imaging showing heterogeneous signal in both liver tumours of the first patient.

despite muscle weakness due to hypokalaemia. This situation resulted in multiple ruptures of muscle fibres (increasing serum values of CPK, AST, ALT, LDH, and elevation of blood levels of myoglobin and myoglobinuria). The increase in myoglobin renal excretion, with subsequent cylinder formation in the nephron or/and direct toxicity to tubular cells, led to acute renal failure.

At physical examination, abdomen, heart, lung, and the neurological system showed normal functioning. Bradypsychia, confusion, and asthenia were the most obvious symptoms. The patient was admitted to the nephrology unit for haemodialysis to treat renal failure. US performed shortly after admission showed mild hepatomegaly, with a few very close hyperecogenic nodules in segment IV, concordant with adenomas (fig 3). FPA of these nodules did not reveal any malignancy.

Coagulation tests were entirely normal, as were AFP serum levels. Serum levels of sex hypophyseal hormones (FSH and LH) were evaluated but were not detected. After diagnosis, the patient underwent three haemodialysis sessions and was encouraged to rest as much as possible, with absolute prohibition on self administering AAS. The biochemical values of the patient returned to normal 20 days later, except for the hormonal serum values. Once the acute renal failure, asthenia, and confusion had resolved, he was discharged from hospital.

US studies performed 1 year later showed a decrease in the size of the hyperecogenic hepatic nodules (not shown) and biochemical analytical values were close to normal.

DISCUSSION

Hepatic adenomas (HA) are uncommon benign neoplasms, usually occurring in young women who take oral contraceptives. In recent times anabolic androgenic steroids (AAS) have been proved to be involved in the development of HA.⁴⁻⁵ Although more than 750 cases of oral contraceptive induced HA have been reported, apparently androgen induced HA are relatively rare. However, the possibility that oral AAS such as stanozolol can induce liver cell proliferation must be taken into account.⁵⁻⁷

HA are not malignant tumours, but surgical intervention may be required if sudden massive bleeding or liver failure occurs; rupture of HA with haemoperitoneum can be a life threatening complication.⁸⁻¹¹ HA are hypervascular tumours containing multiple sinusoids of capillaries with thin walls in which the pressure is exclusively arterial. The connective tissue support is poor and, therefore, bleeding tends to spread diffusely throughout the entire tumour.¹⁰ A non-surgical approach should be considered for androgen induced HA, given that some tumours have regressed after AAS administration was stopped.⁴⁻⁷⁻⁹⁻¹²

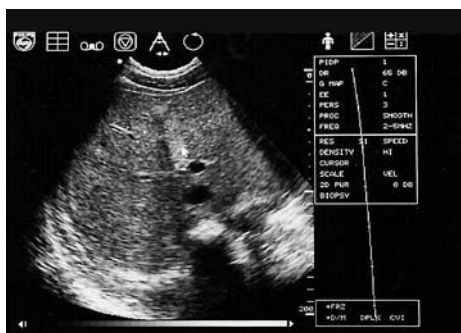

Figure 3 Abdominal ultrasound showing hyperecogenic nodules close together in the liver of the second patient.

One of the problems that HA present is differentiation between HA and hepatocellular carcinomas (HCC). In fact, radiological findings in patient with HA are often similar to those in patients with HCC.²⁻¹⁴ In those cases in which clinical, radiological, and histological distinctions between HA and HCC are difficult to determine, surgical resection, if possible, may be recommended.²⁻⁴ In our patients, histopathological studies of liver specimens obtained by FPA and biopsy allowed us to establish the diagnosis of HA.

Another problem with HA is their potential for malignant transformation, although this point is still controversial. Rapid progression of tumours and tumour obstruction of the intrahepatic portal veins, demonstrated by US, CT, or MRI studies, could indicate the possibility of malignant transformation. For this reason, a careful follow up of HA patients by means of US studies every 6 months is absolutely necessary.²⁻⁸⁻¹⁴⁻¹⁶

Several reasons make it difficult to establish a general strategy of treatment of hepatocellular adenomas: the risk of haemorrhage, the technical difficulties encountered in tumour excision, and the uncertain risk of malignant transformation. These factors determine the prognosis of the disease.⁸⁻¹⁷ In a number of cases, other therapies, such as ethanol injection therapy or radiofrequency ablation, should also be evaluated.⁸ Thus, young men with HA should undergo tumour resection, even when there is no liver failure, rupture, or malignant transformation. However, in the cases here reported hepatic resection has not been performed because of the size and number of the tumours. Furthermore, the fact that following the last test there was an evident decrease in the size of the lesions in both cases opens the possibility that in future years the first patient may be operated on and his lesions resected and in second patient the lesions may regress spontaneously. The clinical evolution of these cases indicates that withdrawal of AAS self administration is the main, and possibly the only, therapeutic tool necessary in cases of early diagnosis of the tumour. In contrast, in evolved cases, with late diagnosis, surgical treatment will probably be necessary.

CONCLUSIONS

Sportsmen, especially bodybuilders, taking anabolic androgenic steroids over a long period should be considered a group at risk of developing hepatic sex hormone related tumours, and should therefore be monitored annually with US examination. Periodic US studies seem to be an adequate screening procedure to detect the development of space occupying lesions. Up to now, when one of these tumours was diagnosed, or even suspected, in an asymptomatic patient, immediate surgical excision was recommended. The risk of intraperitoneal haemorrhage, which can be fatal, justifies more aggressive initial management. Nevertheless, a non-surgical approach for tumours associated with androgens has been suggested because of the regression of tumours after AAS administration was stopped. In any case, after a diagnosis of liver tumours the administration of AAS should cease and the patient should be carefully monitored, preferably twice a year, with biochemical analyses of liver function, AFP serum levels, and US studies.

Authors' affiliations

L Socas, Department of Radiology, Cajal Clinical Centre, Las Palmas de Gran Canaria, Canary Islands, Spain

M Zumbado, O Pérez-Luzardo, L D Boada, Toxicology Unit, Department of Clinical Sciences, Health Sciences Centre, University of Las Palmas de Gran Canaria, Canary Islands, Spain

A Ramos, Department of Physical Education, Faculty of Physical Education, University of Las Palmas de Gran Canaria, Canary Islands, Spain

What is already known on this topic

Hepatic adenomas are uncommon benign tumours usually occurring in young people taking steroid hormones. Recently hepatic adenomas in young people who self administered anabolic androgenic steroids, especially 17- α -alkyl derivatives, have been reported. Surgical resection is recommended because of the risk of malignant transformation or intratumoral bleeding and rupture. However, a non-surgical approach for androgen induced liver tumours should be considered.

C Pérez, Haematology Service, Hospital Materno-Infantil of Gran Canaria, Canary Health Service, Canary Islands, Spain

J R Hernández, Department of Medical and Surgical Sciences, Health Sciences Centre and Hospital Insular of Gran Canaria, University of Las Palmas de Gran Canaria, and Canary Health Service, Canary Islands, Spain

Competing interests: none declared.

Informed consent was obtained from the two patients described in this report.

Correspondence to: Dr L D Boada, Toxicology Unit, Department of Clinical Sciences, Health Sciences Centre, PO Box 550, 35080 Las Palmas de Gran Canaria, Spain; ldominguez@dcc.ulpgc.es

Accepted 22 August 2004

REFERENCES

- 1 **Catlin DH**. Anabolic steroids. In: De Groot LJ, ed. *Endocrinology*. Philadelphia: Saunders, 1995:2362–76.
- 2 **Wilson J**, Griffin J. The use and misuse of androgens. *Metabolism* 1980;**29**:1278–94.
- 3 **Kopera H**. Side effects and contraindications of anabolic steroids. In: Kopera H, ed. *Anabolic-androgenic steroids towards the year 2000*. Vienna: Blackwell-MZV, 1993:262–5.
- 4 **Nakao A**, Sakagami K, Nakata Y, et al. Multiple hepatic adenomas caused by long-term administration of androgenic steroids for aplastic anemia in association with familial adenomatous polyposis. *J Gastroenterol* 2000;**35**:557–62.

What this study adds

The cases reported by us reinforce the importance of withdrawing anabolic-androgenic steroids. In our experience, the first therapeutic approach to androgen induced hepatic adenomas should be, if possible, the absolute prohibition of taking anabolic-androgenic steroids. In some cases, where the size of the tumours is not very large, this therapeutic approach could be sufficient.

- 5 **Degos F**, Laraki R, Abd Alsamad I. Anatomico-clinical conference. Pitié-Salpêtrière Hospital. Case N.1-1994. Multiple hepatic tumors in a woman with idiopathic thrombopenic purpura. *Ann Med Interne (Paris)* 1994;**145**:20–4.
- 6 **Boada L**, Zumbado M, Torres S, et al. Evaluation of acute and chronic hepatotoxic effects exerted by anabolic-androgenic steroid stanozolol in adult male rats. *Arch Toxicol* 1999;**73**:465–72.
- 7 **Stimac D**, Milic S, Dobrila-Dintinjana R, et al. Anabolic/androgenic steroids-induced toxic hepatitis. *J Clin Gastroenterol* 2002;**35**:350–2.
- 8 **Minami Y**, Kudo M, Kawasaki T, et al. Intrahepatic huge hematoma due to rupture of small hepatocellular adenoma: a case report. *Hepatol Res* 2002;**23**:145–51.
- 9 **González A**, Canga F, Cárdenas F, et al. An unusual case of hepatic adenoma in a male. *J Clin Gastroenterol* 1994;**19**:179–81.
- 10 **Hernández-Nieto L**, Bruguera M, Bombi JA, et al. Benign liver-cell adenoma associated with long-term administration of an androgenic-anabolic steroid (methandionone). *Cancer* 1977;**40**:1761–4.
- 11 **Boyd PR**, Mark GJ. Multiple hepatic adenomas and a hepatocellular carcinoma in a man on oral methyltestosterone for 11 years. *Cancer* 1977;**40**:1765–70.
- 12 **Kammula US**, Buell JF, Labow DM, et al. Surgical management of benign tumors of the liver. *Int J Gastrointest Cancer* 2001;**30**:141–6.
- 13 **Al-Otaibi L**, Whitman GJ, Chew FS. Hepatocellular adenoma. *Am J Roentgenol* 1995;**165**:1426.
- 14 **Grazioli L**, Federle M, Brancatelli G, et al. Hepatic adenomas: imaging and pathological findings. *Radiographics* 2001;**21**:877–92.
- 15 **Midorikawa Y**, Ishikawa T, Kubota K, et al. Development of well-differentiated hepatocellular carcinoma in large adenomatous hyperplasia after long-term follow-up: a case report. *Hepatogastroenterology* 2002;**49**:1098–101.
- 16 **Hartgens F**, Kuipers H, Wijnen JA, et al. Body composition, cardiovascular risk factors, and liver function in long term androgenic-anabolic steroids using bodybuilders 3 months after drug withdrawal. *Int J Sports Med* 1996;**17**:429–33.
- 17 **Cheng PN**, Shin JS, Lin X. Hepatic adenoma: an observation from asymptomatic stage to rupture. *Hepatogastroenterology* 1996;**43**:245–8.